

M. Rahman

CASE REPORT

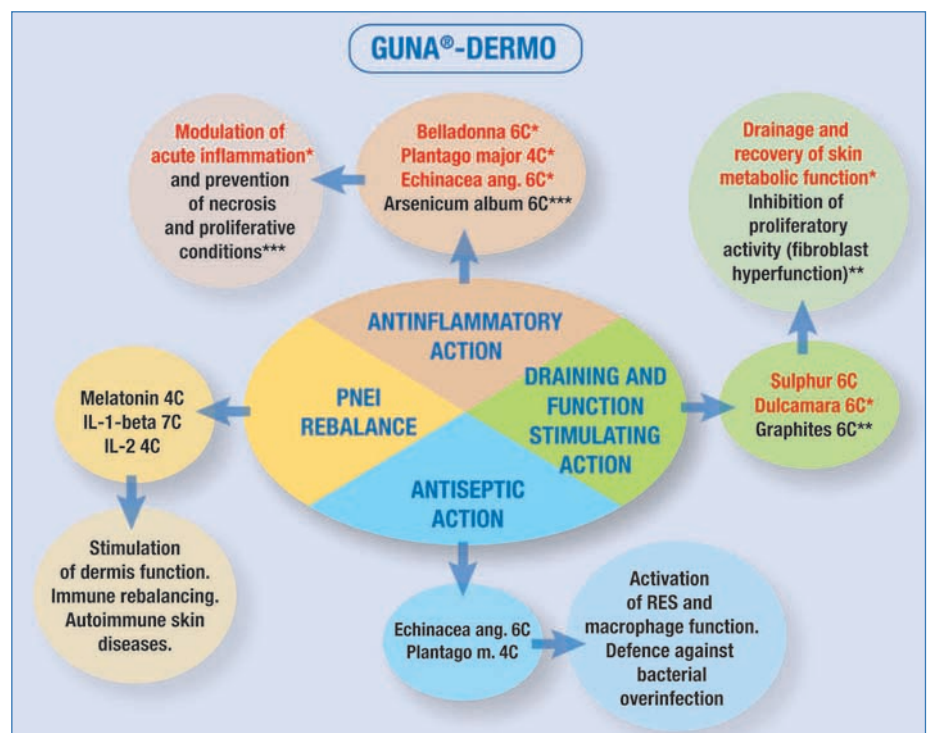
PHYSIOLOGICAL REGULATING MEDICINE AND PEDIATRIC ATOPIC DERMATITIS

Atopic dermatitis is a term that is attributed to the traditional understanding of the histamine mediated reaction leading ultimately to the characteristic symptomatology of atopic eczema. What is described may be part of the triad of **allergy-dermatitis-asthma**. While conventional thinking has described this condition as idiopathic, the non conventional viewpoint is different. Pediatric dermatitis may be viewed as a manifestation of gut dysfunction and imbalances of the non conventional occurring flora, especially manifesting or presenting as food related intolerances. Physiological Regulating Medicine (PRM) sees this condition as an impregnation of the toxins at endodermal level, possibly being held in place by immune miscommunication creating a TH1 and TH2 imbalance and an ensuing deficiency of the TH1 subset of cytokines, such as Interleukins 1, Interleukin 2, Interleukin 4, and INF-gamma. The toxin deposition in children may principally be due to the possibility of heavy metal contamination, such as mercury, aluminum, lead, or vaccination intoxication; it is also conceivable that these exposures may occur in the antenatal or prenatal time.

- The following is a remarkable case of a nine month old boy with significant atopic dermatitis. This child was adopted from South Korea by a Canadian family. The family are long time patients of mine and were quite familiar with the model of non conventional medicine. On my initial visit, in October 2008, his presenting symptoms were diarrhea for seven weeks with concomitant nasal-sinus congestion and an already identified allergy to egg. All vaccinations were supplied up until this point, the 2, 4, 6 month vaccines with no adverse or apparent reactions. The family history is relatively unknown. On my initial visit, I usually conduct an Electrodermal screening (EDS), which is a Bio-feed back mechanism devised by the German Physician Dr. Voll. My techniques revealed that there was respiratory distress, Nervous

System strain or stress and irregularities within the immune system, as well as deficiencies of gut function. My initial prescription, at this point and time, is **ARD Colostrum, one sachet twice a day** and **Eubiflor, 5 drops twice a day**. My second visit in November revealed on subjective and objective findings little change and so the second prescription included **Guna®-Dermo, 10 drops twice a day** which helped to symptomatically manage what was happening at the endodermal functions and to address the immuno deficiency state, I prescribed **Citomix, one to two pellets once a day**.

My assessment was this little boy was using his primary excretory bowels and kidneys especially as a way of elimination. I prescribed **Guna®-Kidney, one pellet once a day**. At this point, I also advised the parents to change the soya based formula to a milk based organic predigested formula, as he was possibly manifesting a soya based reaction. In December, the family returned to report to me that the diarrhea was better and eczema was about 80% better, but



not completely cleared. I added the remedy **Guna[®]Matrix, 5 drops, twice a day** and the homeopathic pellet **Citric acid-ium 4 C, 3 pellets per day** for matrix regeneration and cleansing in the allergic diathesis. In the first week of January, I prescribed to the parents a rotation and elimination type diet. Upon return, in the later part of January 2009, the parents reported almost 100% reversal of the dermatitis situation and a complete reversal of all bowel symptoms. However, to provide more bowel support I added **Guna[®]Bowel, 5 drops once daily**.

Enclosed are the following photos that reveal the remarkable change in the patient's skin. Notice the change from dermatitis occurring from the abdomen (**FIGS. 1, 2**), back (**FIGS. 3, 4**) and face (**FIGS. 5, 6**) to no rash at all. To date, the parents have not had any return of symptomatology. Once again proving the benefits of using the PRM to address drainage and detoxification functions of the dermis by and the regulating effects of the gut. ■

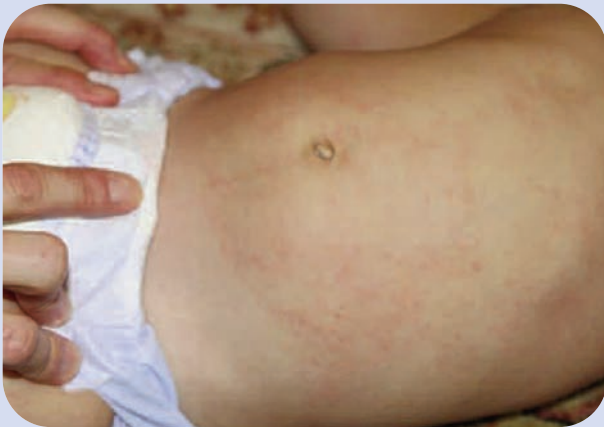

FIG. 1 Abdomen before therapy

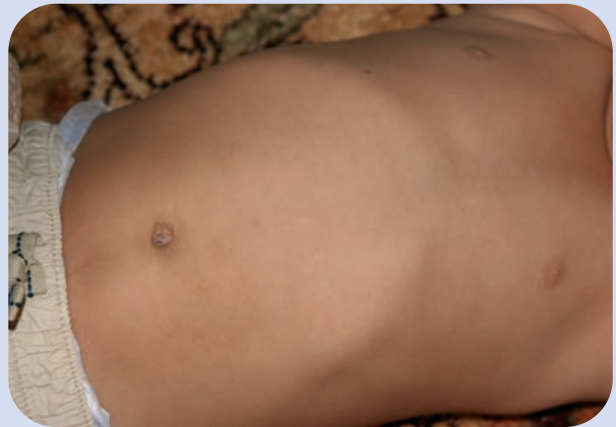

FIG. 2 Abdomen after therapy

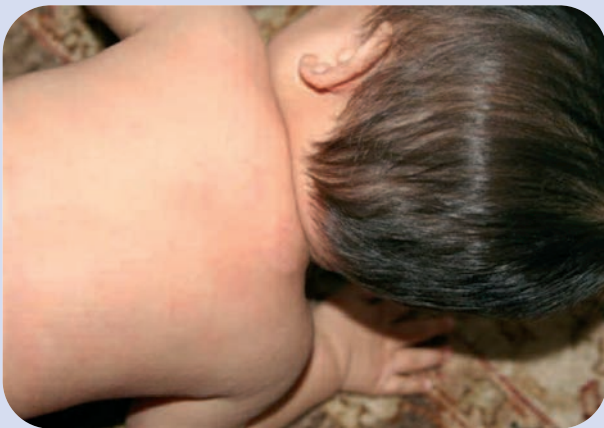

FIG. 3 Back before therapy

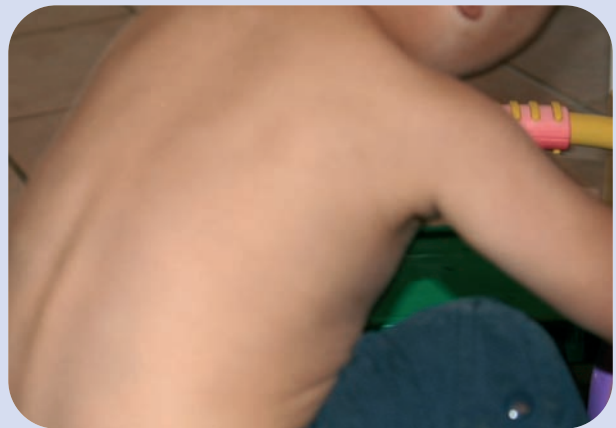


FIG. 4 Back after therapy

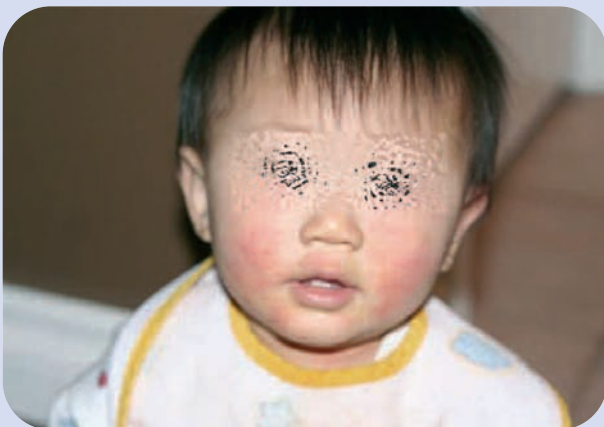

FIG. 5 Face before therapy



FIG. 6 Face after therapy